



D I T R O N D E N T A L
U S A

Aesthetic Implant-Supported Maxillary Restoration in a Periodontally Jeopardized Patient



Fadie Khoury, D.M.D.
Vladislav Dvoyris, D.M.D

Aesthetic Implant-Supported Maxillary Restoration in a Periodontally Jeopardized Patient

Fadie Khoury, D.M.D.ⁱ,
Vladislav Dvoyris, D.M.D.ⁱⁱ,

ⁱ Private practice / Kiryat-Motkin, Haifa, Israel

ⁱⁱ Ditrón Dental, a division of Ditrón Precision LTD / Ashkelon, Israel

INTRODUCTION

The concept of aesthetics, dealing with the nature and characterization of beauty, has been discussed by philosophers as early as in Ancient Greece. However, it was not until the 19th century that aesthetics became a unique academic discipline, and as modernity has put the individual in the spotlight, personal aesthetics play an increasing role in self-perception, confidence and success of men and women alike.^{1,2}

Dentistry has also changed greatly throughout the last century. The introduction of aesthetic materials with improved strength and of novel concepts of oral implantology and osseointegration³, allows dentists today to successfully restore missing and hopeless teeth, enjoying excellent long-term prognosis, natural and highly aesthetic appearance and supreme patient satisfaction.

The latest advancements in the field of aesthetic restoration came with the introduction of CAD/CAM systems, allowing chairside scanning, design and fabrication of high-quality restorations; and of the Digital Smile Design (DSD)⁴ concept, providing an excellent computer-aided tool for dental professionals and technicians performing restorations in the aesthetic zone.⁵

The following case-report shall demonstrate the use of all the aforementioned methods: Digital Smile Design[®], CAD/CAM and implant placement with immediate loading – yielding great results and supreme patient satisfaction.

PATIENT HISTORY

A 54-year old healthy and non-smoking female first appeared in our office in July 2010. Her chief complaint was gum inflammation and mobility of an implant supported restoration of #25. Initial dental evaluation revealed advanced periodontal disease, involving severe loss of attachment at the upper left posterior sextant. (Fig. 1)

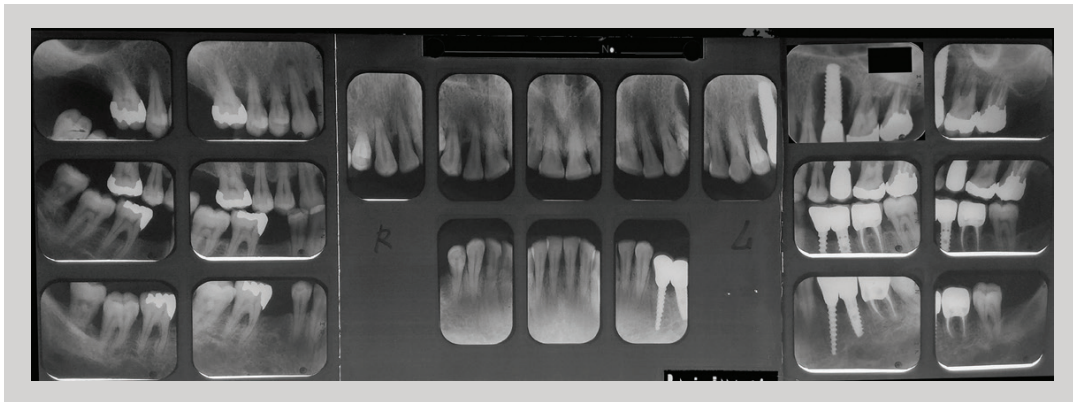


Fig. 1: Full-Mouth Series (7/2010)

Nonetheless, after the initial consult the patient chose to be treated elsewhere. She returned to our clinic after four years, following continued complaints on pain, mobility and unsatisfactory esthetics. It was evident that the #25 implant was removed, and a cantilever bridge X-26-27 was installed instead (Fig. 2), thus further jeopardizing the periodontally involved molars – which by now presented increased mobility, leading to severe discomfort. The patient requested a treatment estimate for the whole maxillary arch.

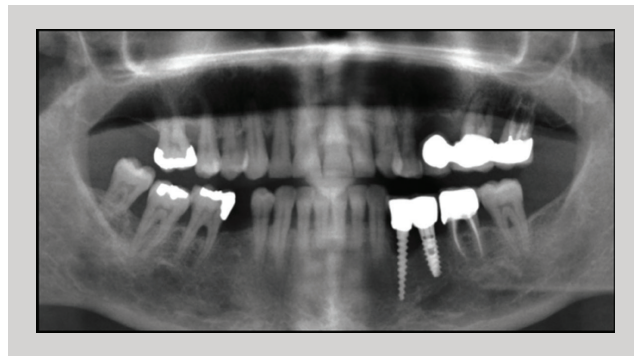


Fig. 2: Initial State Panoramic X-ray (6/2014)

Upon receipt of an updated estimate, the patient returned to the clinic and gave her consent to commence treatment.

CLINICAL AND RADIOGRAPHIC EVALUATION

Initial clinical evaluation revealed severe chronic periodontal disease (*Fig. 3*), leading to moderate-to-severe loss of periodontal attachment in all areas of the patient's mouth and furcation involvement in all mandibular molars. In addition, due to parafunctional habits, the patient presented a reduced vertical dimension of her maxillary incisors and canines, and a gummy smile (*Fig. 4*).

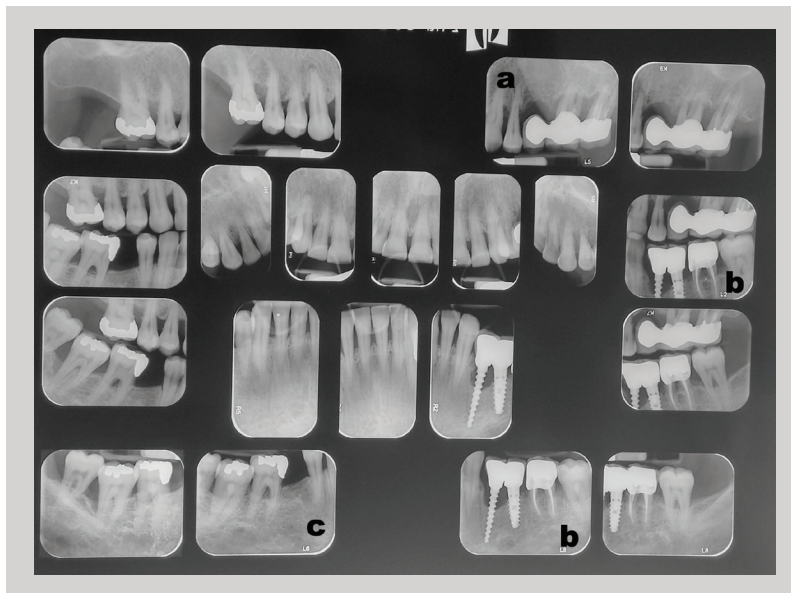


Fig. 3 a-c: Full-Mouth Series (6/2014)

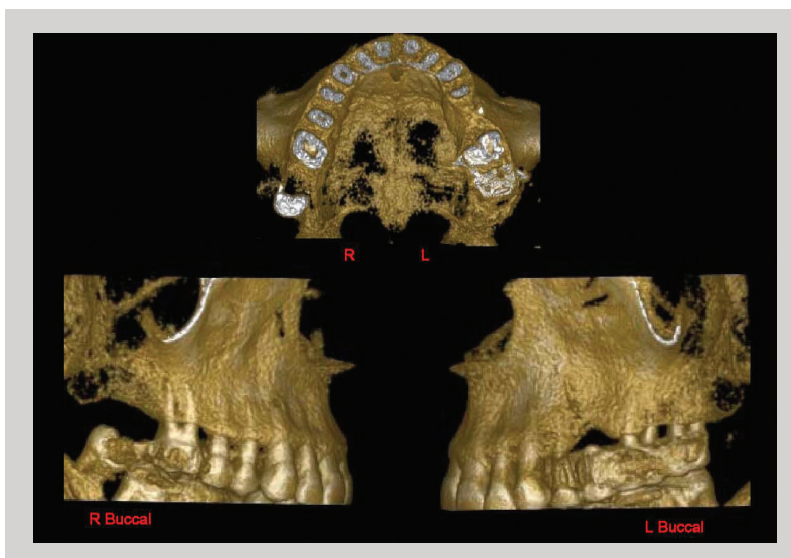


Fig. 4: CT 3D Reconstruction of the Maxilla

The left posterior maxillary sextant demonstrated the most severe loss of periodontal attachment and bone structure (*Fig. 4*).

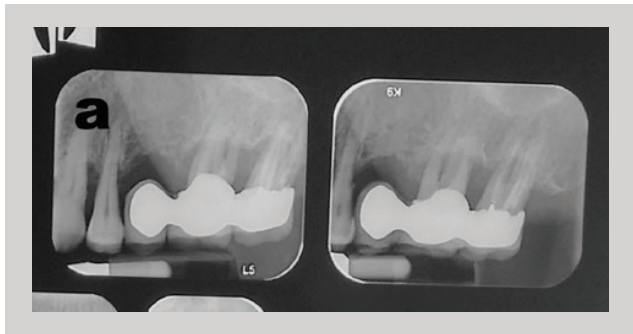


Fig. 3a

While #27 had history of endodontic treatment, it seems that no effort was done to perform RCT on #26 before using it as an abutment (Fig. 3a).

In addition, the patient presented with moderate peri- implantitis around implants #34-35 (Fig. 3b), demonstrating a greatly increased radiographic loss of bone structure within 4 years (2010 to 2014).

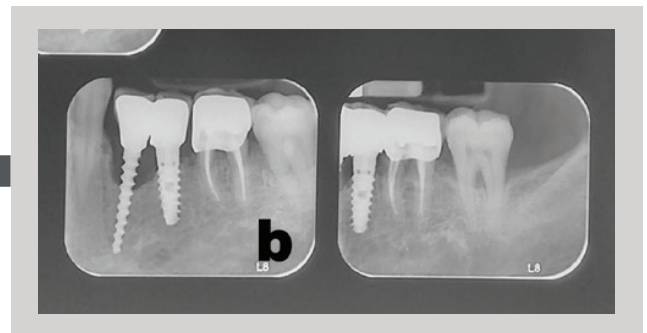


Fig. 3b

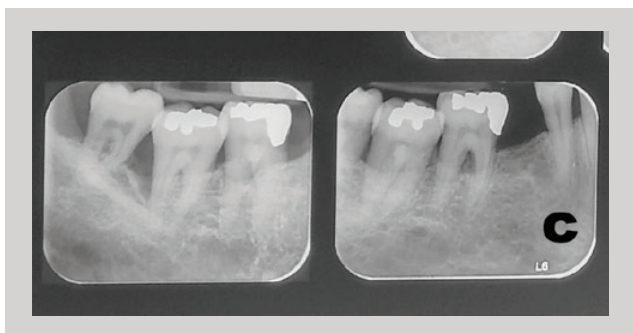


Fig. 3c

Furthermore, tooth #45 was missing, presenting a suitable site for implantation (Fig. 3c).

REATMENT PLAN

We offered the patient the following treatment plan:

1. Oral hygiene instruction, scaling and root planing
2. Extraction of #26-27, bone augmentation with sinus lifting and implant-supported restorations of #25-26-27.
3. Esthetic restoration of #15-25 with laminate veneers, elongating the incisors to "the golden proportion" in order to achieve a proper smile line.
4. Implant-supported restoration of #45

We notified the patient that due to her reduced periodontium, the "black triangles" in gingival embrasures between her teeth are due to remain. However, following presentation of the complete treatment plan, prepared with Digital Smile Design (*The Christian Coachman concept*) (Fig. 5) and superimposed on studio photographs made in our clinic, the patient embraced the treatment plan and gave her consent.

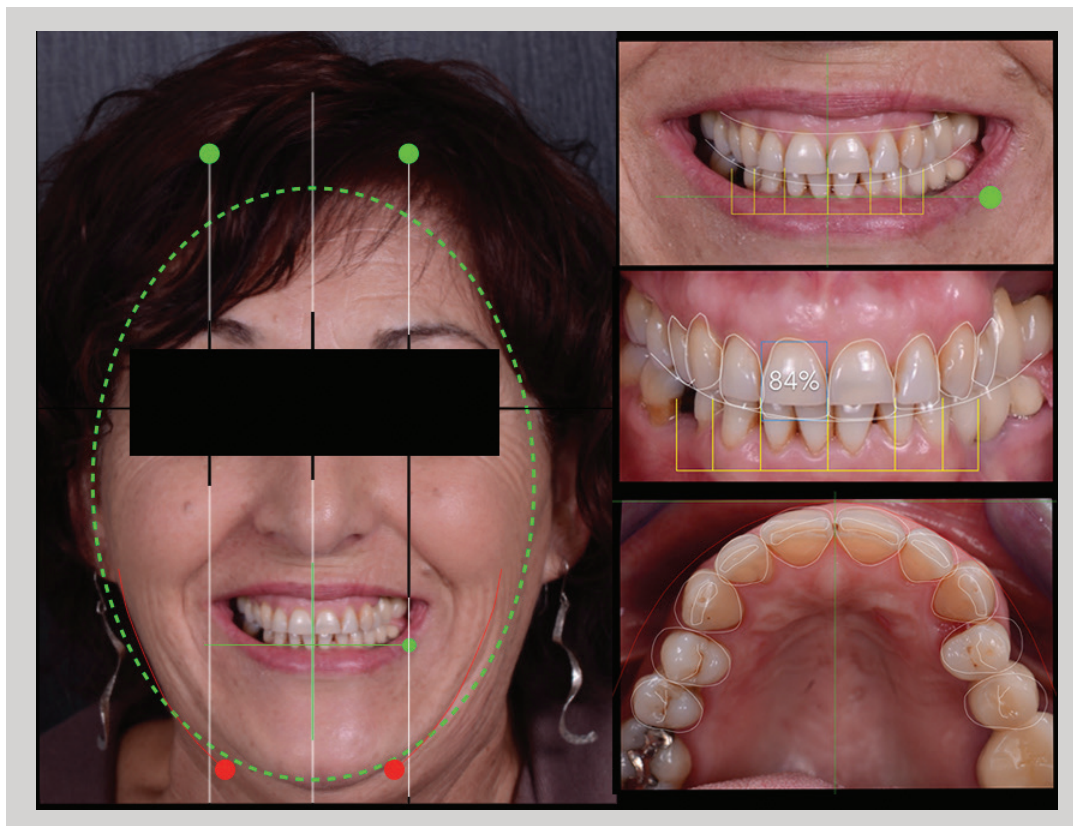

Fig. 5: Initial Facial Aesthetics and Digital Smile Design

TREATMENT

After an uncomplicated extraction of #26-27, bone augmentation with bovine bone an (Endobon Xenograft Granules, 1-2mm/Zimmer Biomet, Warsaw, IN, USA) and a closed sinus lifting were performed in the same session, following which 3 implants were placed at the #25-26-27 sites (#25 – MPI™ D-3.75mm L-13mm; #26-27 - MPI™ D-4.2mm L-11.5mm/Ditron Dental, Ashqelon, Israel) and stabilized with a 45ncm torque. In addition, aimed at the improvement of esthetics and gingival support, we have performed gingival augmentation at the #25 buccal gingiva, using a sub-epithelial connective tissue graft from the adjacent palatal region (Fig. 6a-n). The implants were provisionalized with temporary PMMA crowns. Despite not being the preferred option in this case, the excellent primary stability of the implants allowed their immediate loading.

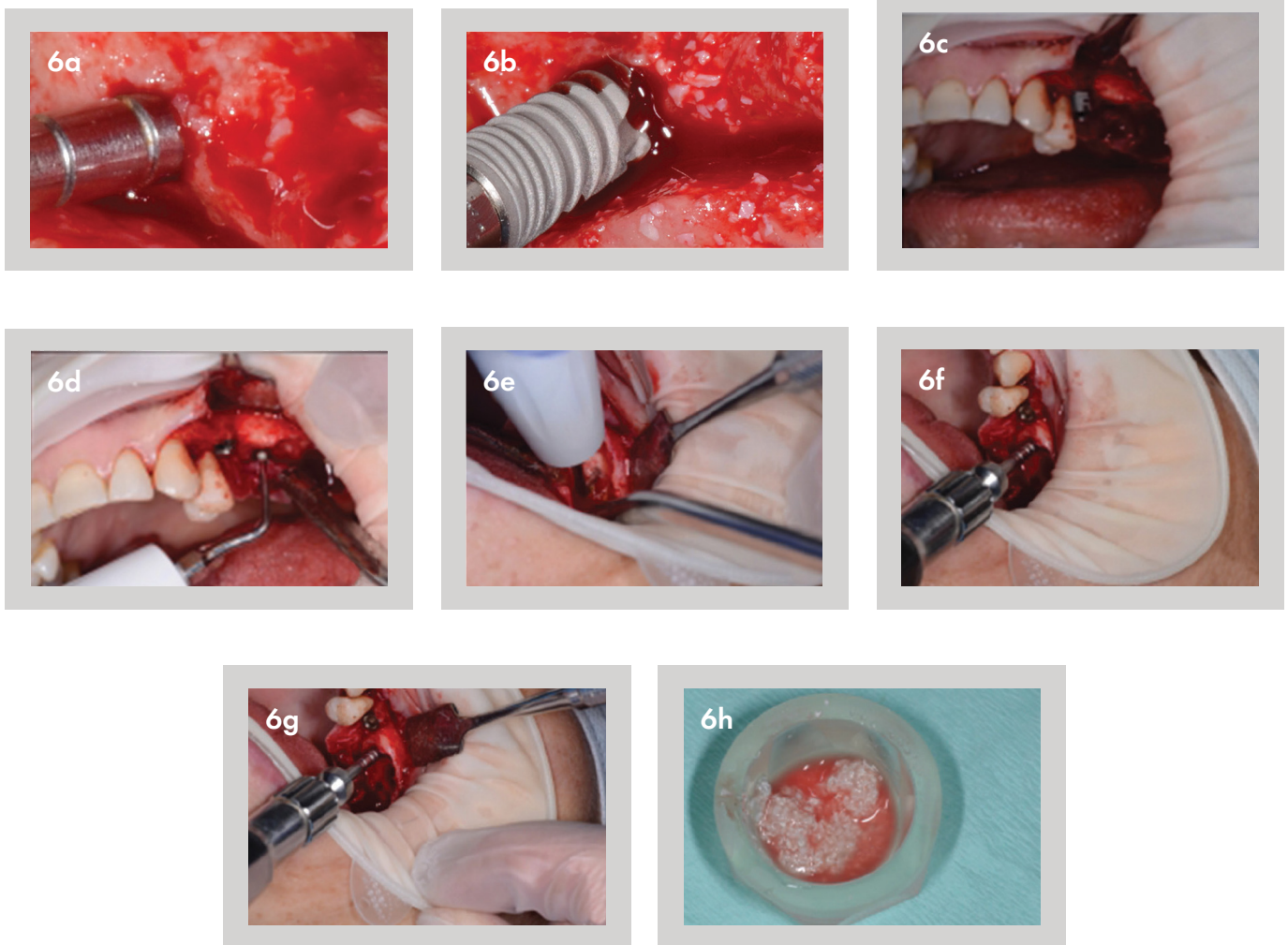
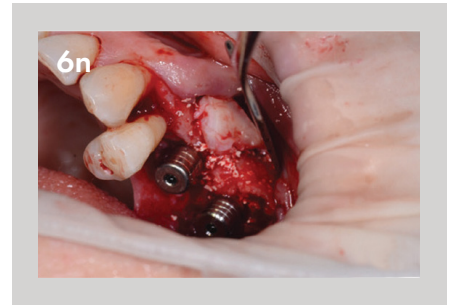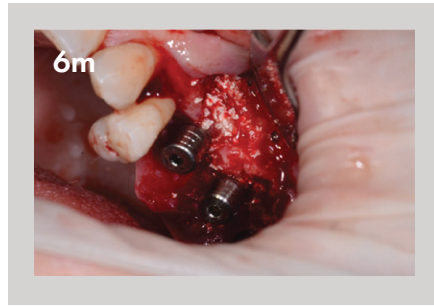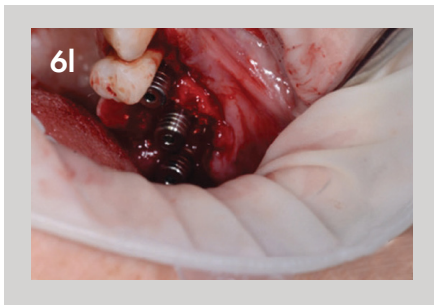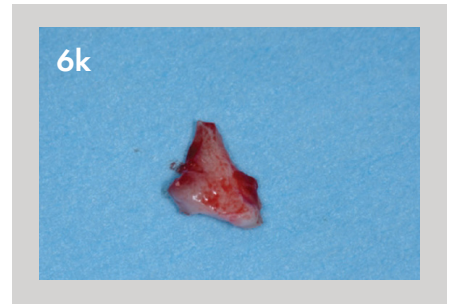
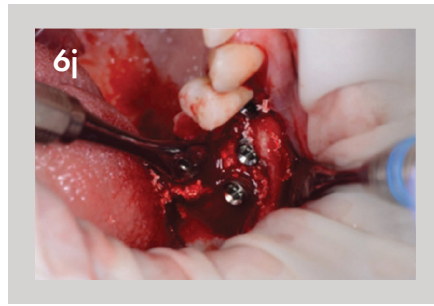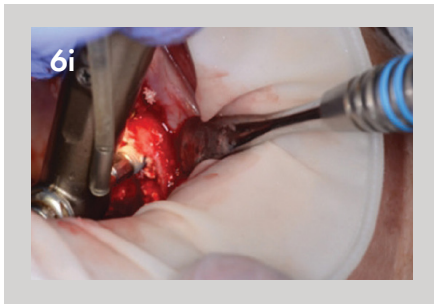


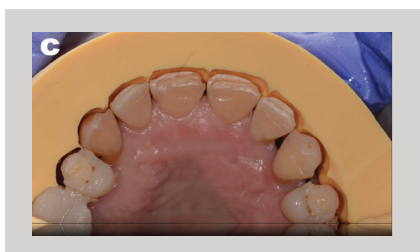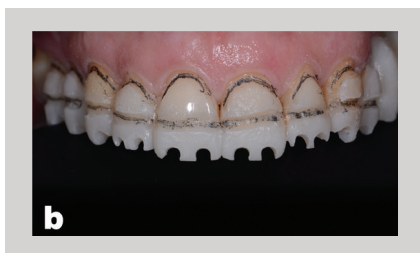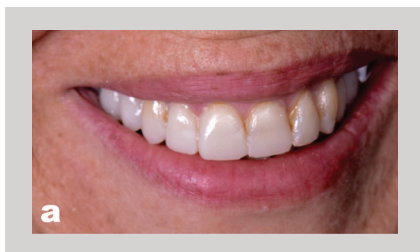Fig. 6 a-o (continue in next page):
Implant Placement with Bone and Gingival Grafting at #25-27



During the healing period, the patient has undergone regular checkups. Two months after the procedure, an additional implantation (*MPI™ D-3.75mm L-10mm*) was performed at the #45 site, combined with an open flap debridement of the periodontal defect at #46.



One month later, we restored the esthetic zone. A composite mockup was built on the patient's teeth #15-25 (Fig. 7a) and scanned with CEREC OmniCam (*Sirona, Bensheim, Hesse, Germany*). Silicone impression of the mockup was taken (Fig. 7c), and the teeth were prepared for laminate veneers through the mockup (Fig. 7b,d,e) and scanned.

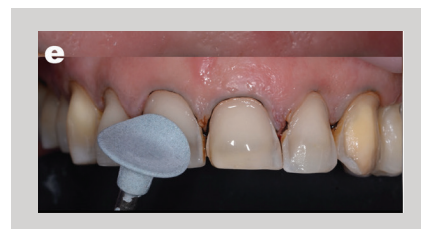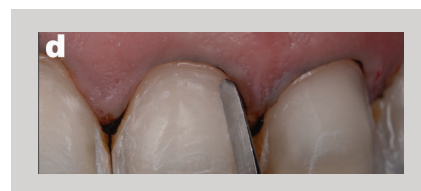


Fig. 7 a-e: Composite Mockup and Preparation for Laminate Veneers

Temporary restorations were then prepared using the silicon index, and cemented in the point-etch technique (Fig. 8).

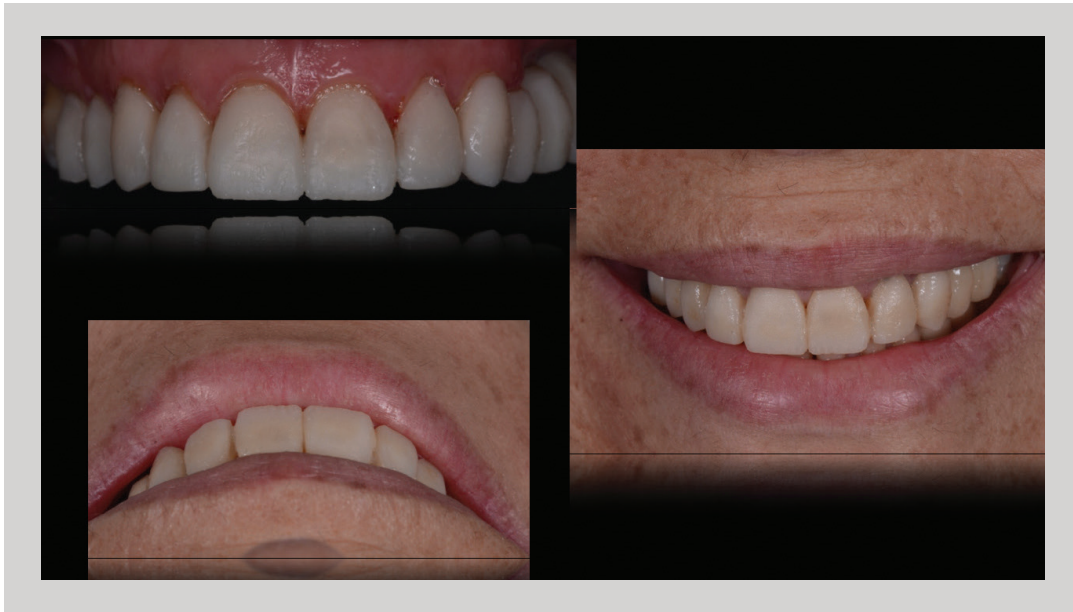

Fig. 8: Temporary Laminate Veneers

The permanent restorations were designed with CEREC software (Fig. 9a-b) and immediately fabricated on a CEREC In-Lab milling unit, using LT-A1-C14 IPS e.max CAD blocks (Ivoclar Vivadent, Amherst, NY, USA).

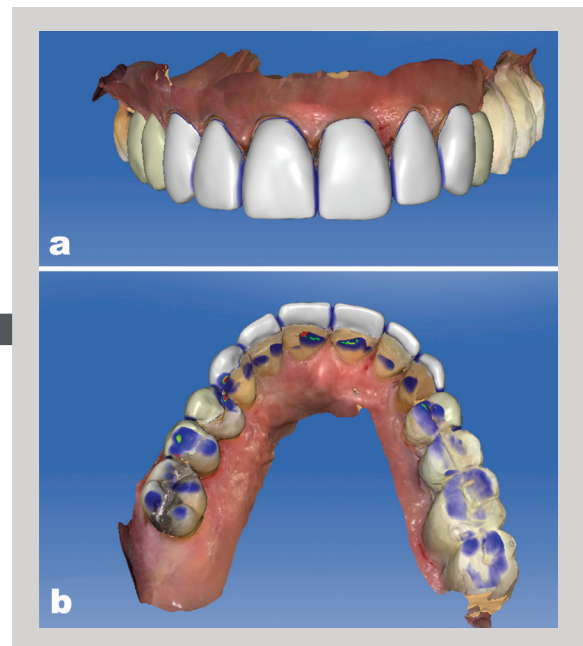


Fig. 9: Laminate Veneers Design on CEREC Software

The restorations were then externally stained in-office (*IPS Empress Shades and Stains, Ivoclar Vivadent, Amherst, NY, USA*) and delivered to the patient (*Fig. 10*).

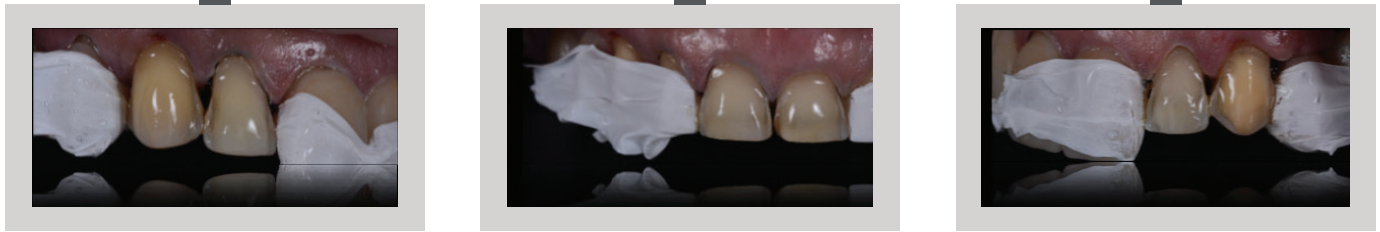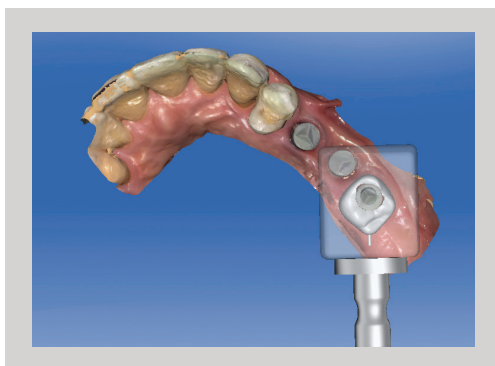


Fig. 10: Laminate Veneers Cementation

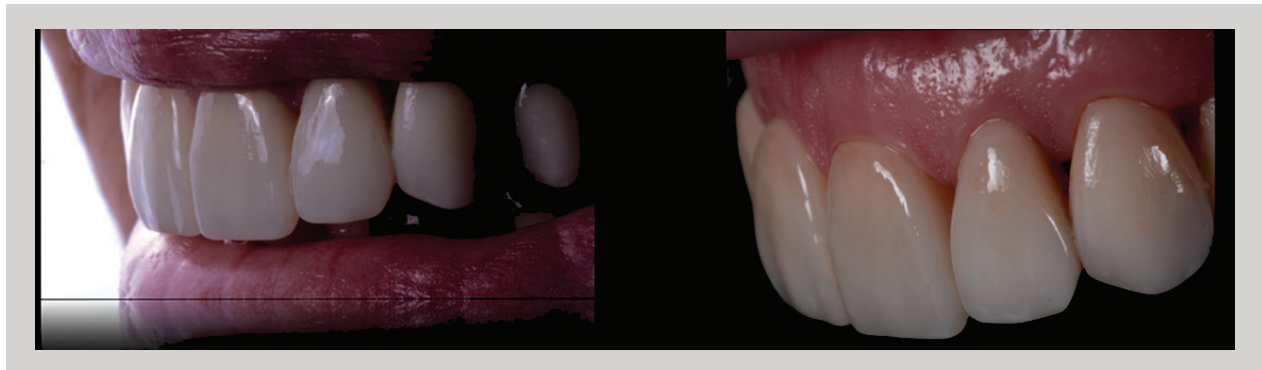

Fig. 11: Laminate Veneers – End Result

Due to her complaint on biting her lower lip, she required some time to adjust to the new, elongated shape of her incisors. The laminates were permanently cemented a month later (*Fig. 11*).



**Fig. 12: Posterior Implant-Supported Crown
Design with CEREC Software**

Another month later, Sirona TiBase abutments (*Sirona, Bensheim, Hesse, Germany*) were fitted to the implants and scanned with CEREC OmniCam (*Fig. 12*). Screw-retained crowns were later milled on a CEREC In-Lab milling unit, and fitted to the implants. Screws were covered with Teflon and composite resin.

Final studio photography and videography was performed (Fig. 13), and the patient has expressed her satisfaction with the final esthetic and functional results (Fig. 14).

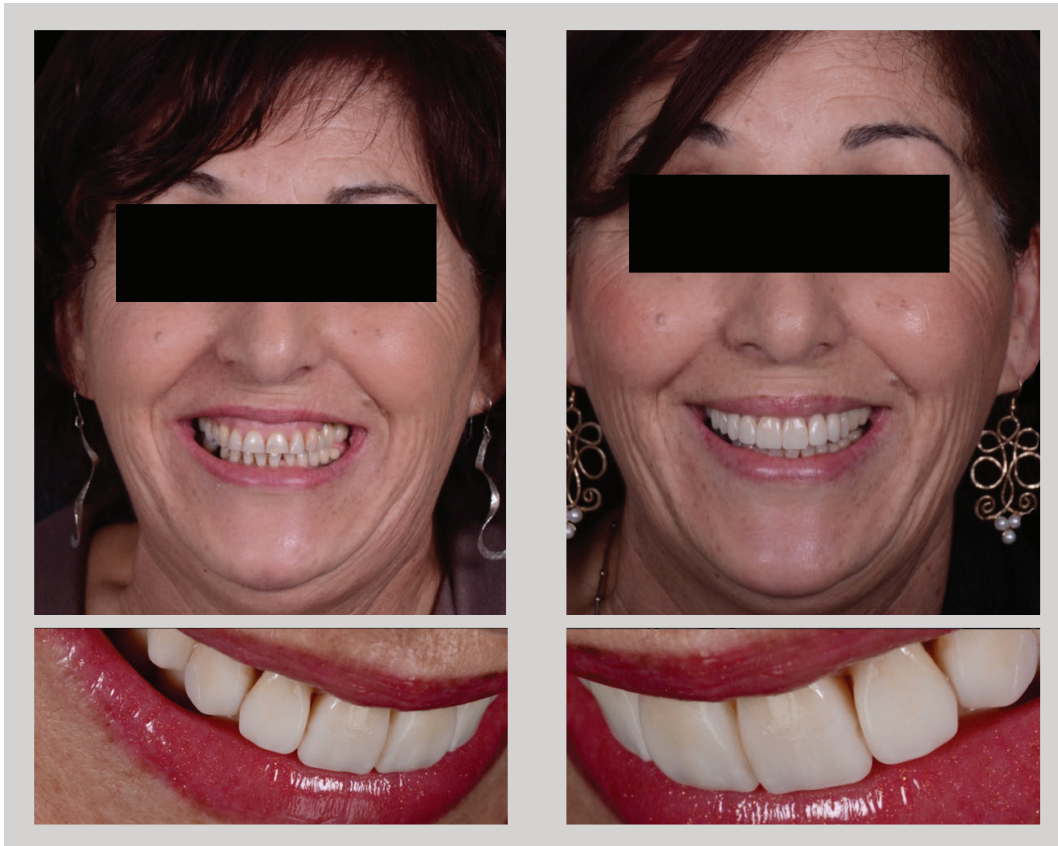

Fig. 13: Final Photographic Session (8/2015)

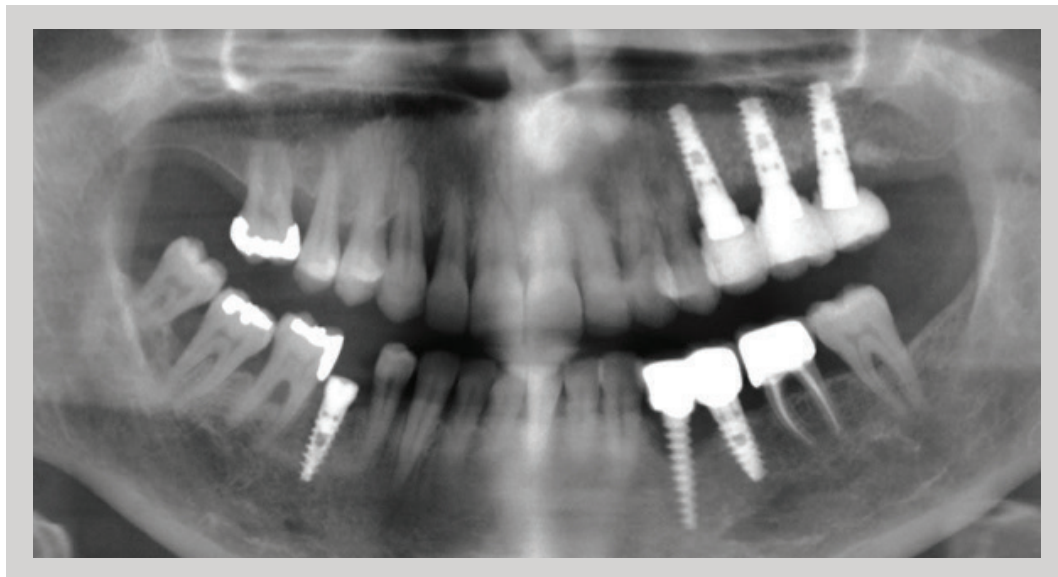


Fig. 14: Final Panoramic X-ray (8/2015)

DISCUSSION

The treatment process presented above utilized some of the most advanced materials and technologies available to dental professionals today. In optimal case scenarios, these technologies often allow streamlining the treatment and shortening it, oftentimes to a single appointment. The use of implant-supported restorations prolongs the treatment, as even supreme primary stability could not bear the loads produced by permanent restorations, and thus partially-loaded provisionalization or even complete coverage of the implant are required to promote healing and osseointegration.⁷

Nonetheless and in spite of the abovesaid, the patient in our case endured suffering and inconvenience for almost five years. Perhaps financial issues⁸ were a major factor in her prolonged consideration and unfortunate choice of a cheaper, seemingly less-complicated treatment that eventually (and expectedly) yielded poor results.

Bridges, although proven as clinically sound restorative solutions when properly placed⁹, can pose a grave danger to the supporting teeth in a periodontally compromised dentition.¹⁰ Excessive occlusal stress applied to the abutment teeth¹¹ will lead, over time, over time, to increased mobility and further loss of attachment. It would be, thus, unwise to restore mobile teeth with bridges, unless the bridge may function as a splint and reduce overall mobility and occlusal trauma.¹² However, in cases where a single tooth is missing or a single implant fails, it is advisable to diagnose the cause prior to treatment, and even if the adjacent teeth are completely sound and intact, an implant supported restoration would be the least-invasive and most successful treatment modality,¹³ and should be the treatment of choice in the majority of cases.

The use of advanced visualization technologies has revolutionized our ability to present treatment options and simulate end-results, and greatly improved doctor-patient communication. However, only the introduction of CAD/CAM technologies allowed precise fabrication of the final restorations, and in-clinic CAD/CAM has greatly streamlined the process and brought "same-day prosthodontics" from science fiction to reality. With time, these systems, as well as advanced implant technologies, become more and more widespread, accessible and affordable to most of our patients, providing them excellent and long-lasting smiles for years to come.

Dr. Fadie Khoury, graduated with honors from the Faculty of Dentistry at the University of Sofia, Bulgaria, in 1993. He is the owner and medical director of the Center for Esthetics and Implant Dentistry in Kiryat-Motskin, Haifa, Israel. Dr. Khoury continues to learn and develop professionally by participating and lecturing in continuing education programs, courses, conferences and seminars in Israel and abroad. dr.fkhoury@gmail.com.

Edited and prepared by Dr. Vladi Dvoyris, DMD for Ditron Dental, a division of Ditron Precision LTD

REFERENCES

1. Gavric A, Mirceta D, Jakobovic M, Pavlic A, Zrinski MT, Spalj S, Craniodentofacial characteristics, dental esthetics-related quality of life, and self-esteem, Am J Orthod Dentofacial Orthop. 2015 Jun;147(6).
2. Pithon MM et al, Perception of Esthetic Impact of Smile Line in Complete Denture Wearers by Different Age Groups, J Prosthodont. 2015 Sep 15. doi: 10.1111/jopr.12355. [Epub ahead of print].
3. Albrektsson T, Brånemark PI, Hansson HA, Lindström J, Osseointegrated titanium implants. Requirements for ensuring a long-lasting, direct bone-to-implant anchorage in man, Acta Orthop Scand. 1981;52(2):155-70.
4. Arias DM, Trushkowsky RD, Brea LM, David SB, Treatment of the Patient with Gummy Smile in Conjunction with Digital Smile Approach, Dent Clin North Am. 2015 Jul;59(3):703-16.
5. Kurbad A, Kurbad S, Cerec Smile Design--a software tool for the enhancement of restorations in the esthetic zone, Int J Comput Dent. 2013;16(3):255-69.
6. Paolucci B et al, Visagism – the art of dental composition, QDT, 2012, 35:187.
7. DeBruynH,RaesS,OsmanPO,CosynJ,Immediate loading in partially and completely edentulous jaws: a review of the literature with clinical guidelines, Periodontol 2000. 2014 Oct;66(1):153-87.
8. Scheuber S1, Hicklin S, Brägger U, Implants versus short-span fixed bridges: survival, complications, patients' benefits. A systematic review on economic aspects, Clin Oral Implants Res. 2012 Oct;23 Suppl 6:50-62.
9. Brægger U et al, Complication and failure rates of fixed dental prostheses in patients treated for periodontal disease, Clin Oral Implants Res. 2011 Jan;22(1):70-7.
10. Stasinopoulou I, Manda M, Galanis C, Koidis P, The effect of type of restoration on the stress field developed in terminal abutments with severely reduced periodontal support and coronal structure, J Prosthet Dent. 2013 Oct;110(4):303-12.

11. Guo Y, Tang L, Pan YH, Three-dimensional finite element analysis of the stress in abutment periodontal ligament of cantilever fixed bridge under dynamic loads, *Zhonghua Kou Qiang Yi Xue Za Zhi*. 2009 Sep;44(9):553-7.
12. Chalifoux PR, Periodontal splinting of anterior teeth, *Pract Periodontics Aesthet Dent*. 1991 Sep;3(6):21-8.
13. Muddugangadhar BC et al, Meta-analysis of Failure and Survival Rate of Implant- supported Single Crowns, Fixed Partial Denture, and Implant Tooth-supported Prostheses, *J Int Oral Health*. 2015 Sep;7(9):11-7.



D I T R O N D E N T A L
U S A

For More Information:

www.ditrondentalusa.com

Tel: 844-434-8766

555 Corporate Drive, Suite 160

Ladera Ranch, CA 92694

STUDY-02/ver01